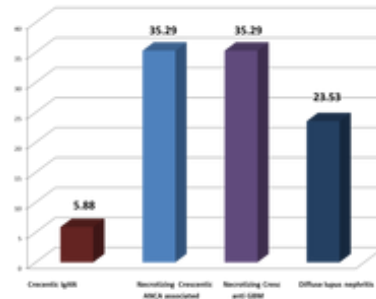


Nephropath Teaching point: 2 - Diffuse alveolar haemorrhage and RPRF in a woman receiving treatment for acne



These are the results of first nephropath teaching point question " Lambda light chain dominance in DIF studies is a useful diagnostic clue of which glomerular disease". Majority of respondents (47.1%) thought that this would imply monoclonality, IgA nephropathy (which is the correct answer) was a not so close second!

Lai et al had shown that patients with primary IgA nephropathy display a unique immunologic response characterized by a predominance of IgA with lambda light chains in circulation. Same authors also showed the predominance of lambda light-chain IgA1 in the serum of patients with IgA nephropathy and also demonstrated that mesangial IgA deposits in IgA nephropathy consist mainly of IgA with lambda light chains despite the fact that the normal ratio of kappa to lambda light-chain-containing immunoglobulin in human serum is two to one. This lambda light chain predominance is in practice an extremely useful phenomenon, particularly useful when differentiating IgA nephropathy from IgA dominant post infectious glomerulonephritis and in borderline cases with not so intense IgA staining or co-dominant staining of another immunoglobulin sub class!